

PATIENT

Juno Davis

PRESENTING CLINICAL SIGNS

History: Possible seizure vs hypoxia vs hypoglycemia.

SPECIES

Canine

HOLTER MONITOR FINDINGS AND RHYTHM ASSESSMENT

Time analyzed	23:07h
Mean heart rate	122bpm
Maximum heart rate	225bpm
Minimum heart rate	68bpm
VPCs	0
APCs	13 singles

BREED

Pomeranian

SEX

Male

Interpretation: Underlying normal sinus rhythm with presumably appropriate rate variation (no diary available). Rare single APCs noted. Single sinus pause (2.5s) noted at 6:37pm during period of relative bradycardia, presumably when sleeping. No escape foci noted.

AGE

11 years

Rhythm diagnosis: Sinus rhythm with rare APCs and a single sinus pause.

WEIGHT

12.9 lbs

RECOMMENDATIONS

Overall normal recording, with rare single APCs and a single sinus pause. Both can be normal in senior dogs; however, no diary was available to confirm. If the patient was sleeping when the pause occurred, this is considered normal. If the patient was alert and active, this is abnormal and may suggest early sinus node dysfunction. No further conclusions can be made without more information; however, suspicion is low in this case.

INTERPRETED BY

Maggie Machen Lamy,
DVM, DACVIM
(Cardiology)

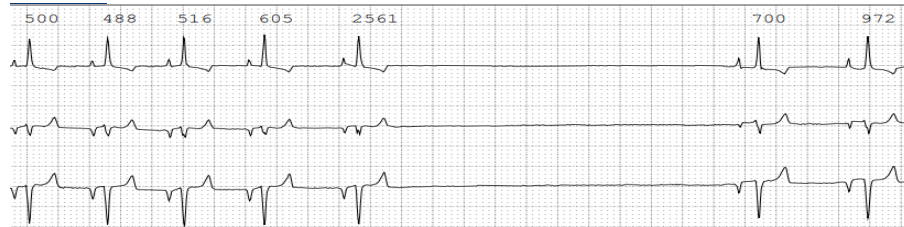
Single APCs are of little concern, and are most commonly a normal finding if low frequency.

IMAGING PERFORMED BY

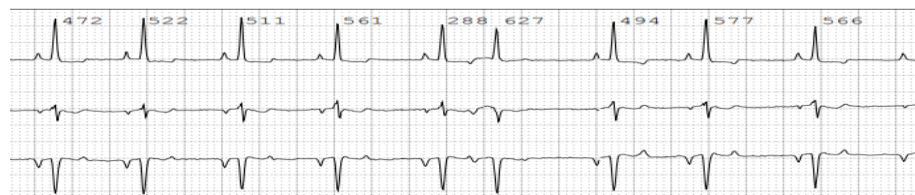
While these findings may reflect early conduction disease in a senior dog, the cause of the episodes remains unknown. Even if early sinus node dysfunction is present, a 2.5s pause is unlikely to cause symptoms. Full systemic evaluation is suggested in a senior pet, with an echocardiogram if a heart murmur is present.

No treatment is indicated based upon what is seen here. Reassess based upon clinical progression.

IMAGES



Sinus pause



APC

HOSPITAL NAME

Rockaway Animal
Hospital

REFERRING VET

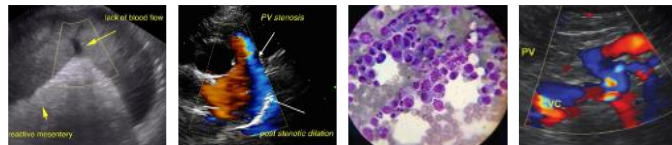
Dr. Maniar

INVOICE

30181

DATE

4/11/23



PATIENT

Juno Davis

The information and recommendations provided are based on the images presented by the referring veterinarian. No evaluation can be communicated regarding pathology that was not visible in the image/video clips provided.

SPECIES

Canine

Thank you for this referral. If the clinical or image interpretation does not parallel your findings or if I can be of any further assistance, please contact me.

BREED

Pomeranian

Maggie Machen Lamy, DVM

Diplomate of the American College of Veterinary Internal Medicine (Cardiology)

info@sonopath.com

SEX

Male

AGE

11 years

WEIGHT

12.9 lbs

INTERPRETED BY

Maggie Machen Lamy,
DVM, DACVIM
(Cardiology)

**IMAGING
PERFORMED BY**

HOSPITAL NAME

Rockaway Animal
Hospital

REFERRING VET

Dr. Maniar

INVOICE

30181

DATE

4/11/23